



Bilateral locked posterior shoulder dislocation overlooked for 15 months treated with the modified McLaughlin procedure: A case report

Murat Saylık, MD¹ , Kemal Gökkuş, MD² 

¹Department of Therapy and Rehabilitation, Mudanya University Vocational School, Bursa, Türkiye

²Department of Orthopedics and Traumatology, Başkent University Alanya Research and Practice Center, Antalya, Türkiye

A locked posterior shoulder dislocation (LPSD) can present in three forms: fracture-dislocation, impression fracture, and isolated dislocation without fracture.^[1] An epileptic seizure causing severe contractions in the body is the most common cause of posterior shoulder dislocation,^[2] followed by electrocution and trauma. In addition, LPSD accounts for 2 to 4% of all shoulder dislocations, and the annual incidence is 0.6 per 100,000 individuals.^[3]

The first posterior dislocation causes an impression fracture (reverse Hill-Sachs lesion) of the anteromedial humeral head in 30 to 90% of cases.^[4,5] If the reverse Hill-Sachs lesion accounts for more than 20% of the articular surface of the humeral head, instability may develop during the internal

Received: October 03, 2022

Accepted: December 06, 2022

Published online: December 27, 2022

Correspondence: Kemal Gökkuş, MD. Başkent Üniversitesi Alanya Araştırma ve Uygulama Merkezi, Ortopedi ve Travmatoloji Kliniği, 07400 Alanya, Antalya, Türkiye.

E-mail: kemalg@baskent.edu.tr

Doi: 10.52312/jdrs.2023.869

Citation: Saylık M, Gökkuş K. Bilateral locked posterior shoulder dislocation overlooked for 15 months treated with the modified McLaughlin procedure: A case report. Jt Dis Relat Surg 2023;34(1):i-viii.

©2023 All right reserved by the Turkish Joint Diseases Foundation

This is an open access article under the terms of the Creative Commons Attribution-NonCommercial License, which permits use, distribution and reproduction in any medium, provided the original work is properly cited and is not used for commercial purposes (<http://creativecommons.org/licenses/by-nc/4.0/>).

ABSTRACT

Neglected bilateral posterior shoulder dislocation is a rare injury caused primarily by an epileptic seizure. The injury is usually associated with a reverse Hill-Sachs lesion in the anteromedial aspect of the humeral head. The modified McLaughlin technique may avoid instability and osteoarthritis when 20 to 40% of the articular surface is affected by reverse Hill-Sachs. In this article, we present the clinical results of a case overlooked in the literature for the longest time, i.e., for 15 months. A 46-year-old male patient was receiving treatment for epilepsy for five years. There was no fall or trauma in the four seizures he had during this time. The last seizure was 15 months ago. When the patient presented to our clinic, both shoulders were symmetrically deformed, the anterior shoulder contour disappeared (empty socket sign), and there was a loss of upper contour. The computed tomography (CT) scan revealed a posteriorly locked dislocation with a reverse Hill-Sachs lesion in 32% of the left shoulder and 36% of the right shoulder. We applied the modified McLaughlin procedure to the dominant right shoulder and, two months later, we used it to the left shoulder (with a graft taken from the anterior superior iliac spine). At one-year of follow-up, both shoulders were moderately functional: forward elevation left 70° and right 50°, abduction left 40° and right 60°, and internal rotation: the back of the hand could touch the fifth lumbar vertebra. Meanwhile, the patient did not suffer from recurrent dislocation. The pre- and postoperative Constant-Murley Scores for the right and left shoulder were 30/52 and 11/48, respectively. Although the operational outcomes using the modified McLaughlin technique were not ideal, with no recurrence, the patient seemed to be satisfied with this outcome. In conclusion, in neglected locked shoulder fracture-dislocations, the modified McLaughlin technique is a method that can respond to the pathophysiology by eliminating reverse Hill-Sachs lesion.

Keywords: Bilateral, fracture dislocation, posterior, shoulder dislocation, shoulder instability.

rotation of the arm.^[6,7] Therefore, if the reverse Hill-Sachs lesion is greater than 20%, surgical treatment should be performed to prevent instability, even if closed shoulder reduction is possible.^[7-9]

The surgical treatment method depends on the size of the reverse Hill-Sachs lesion, the degree of instability, the neglected period of dislocation, and the patient's functional expectations. After the 1950s, efforts to improve surgical treatment of old, unreduced posterior dislocations increased. However, even if a neglected LPSD is discovered late, urgent surgical treatment is required.^[7-9]

McLaughlin^[9] reported three cases with old unreduced posterior dislocations and described the procedure under his name as the McLaughlin procedure. This procedure aims to close the reverse Hill-Sachs lesion with transposition of the subscapularis tendon.^[9] McLaughlin first described subscapularis tenodesis for a reversed Hill-Sachs lesion.^[9]

Hawkins et al.^[10] developed this method further in 1987 and transferred the subscapularis tendon along with the lesser tuberosity in the reversed Hill-Sachs lesion and referred to the method as the modified McLaughlin method. They argued that this method could restore the Hill-Sachs lesion more anatomically, and the bony fixation was more reliable.

The literature search in this article was challenging due to terminological problems and difficulty finding the right keywords, as some studies refer to the glenoid-induced impression fracture on the anterior aspect of the humeral head (also known as reverse Hill-Sachs) as a fracture-dislocation. Therefore, this literature search was performed using the terms "locked posterior shoulder dislocation" and "posterior shoulder fracture-dislocations." After a thorough literature search, there were 33 papers.^[1,6,8,11-39]

In this article, we present a case overlooked in the literature for the longest time; i.e., for 15 months and

discuss the surgical treatment of a bilateral neglected LPSD case with a 32% reverse Hill-Sachs lesion on the right shoulder and a 36% lesion on the left shoulder. This case report follows the CARE guidelines.^[40]

CASE REPORT

A 46-year-old male patient was receiving epilepsy treatment for five years. There was no fall or trauma history during the four seizures he had. He had no known orthopedic condition and had his last episode 15 months prior. When the patient presented to our clinic, both shoulders were symmetrically deformed, the anterior shoulder contour disappeared (empty socket sign), and there was a loss of upper contour. On physical examination, a posterior mass was noted, and the range of motion was limited and painful in both shoulders. The patient could not move either shoulder actively or passively. No neurovascular abnormalities were noted in either arm.

Since the patient's last seizure 15 months ago, anteroposterior radiographs of both shoulders were repeated at regular intervals at external healthcare facilities. Unfortunately, other facilities overlooked the diagnosis, until the patient presented our clinic. The CT scan revealed a posteriorly locked dislocation with a reverse Hill-Sachs lesion in 32% of the left shoulder and 36% of the right shoulder (Figure 1). In the right shoulder, a posterior glenoid corner fracture caused bone loss.

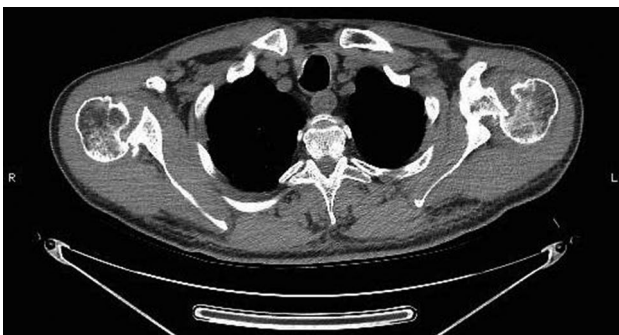

FIGURE 1. Preoperative computed tomography scan (axial views) showing posteriorly locked dislocation with a reverse Hill-Sachs lesion in 32% of the left shoulder and 36% of the right shoulder.

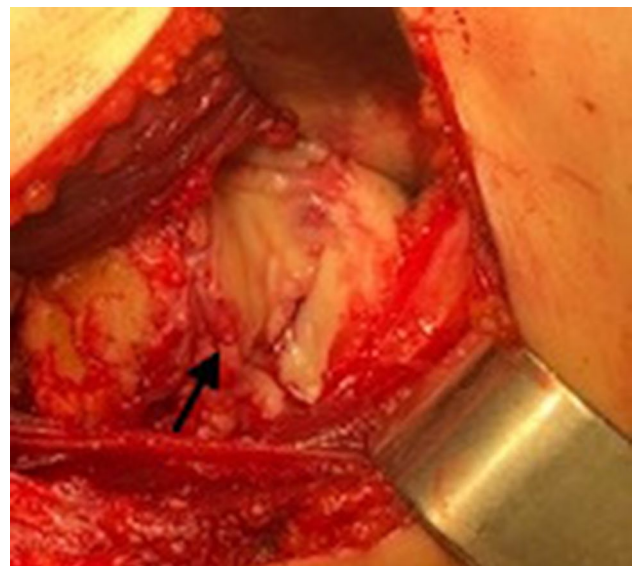


FIGURE 2. With the patient in beach chair position the intraoperative photograph was taken to demonstrate the anterior aspect of the humeral head. Note the wedge-shaped impression fracture (black arrow) on the anterior aspect of the humeral head.

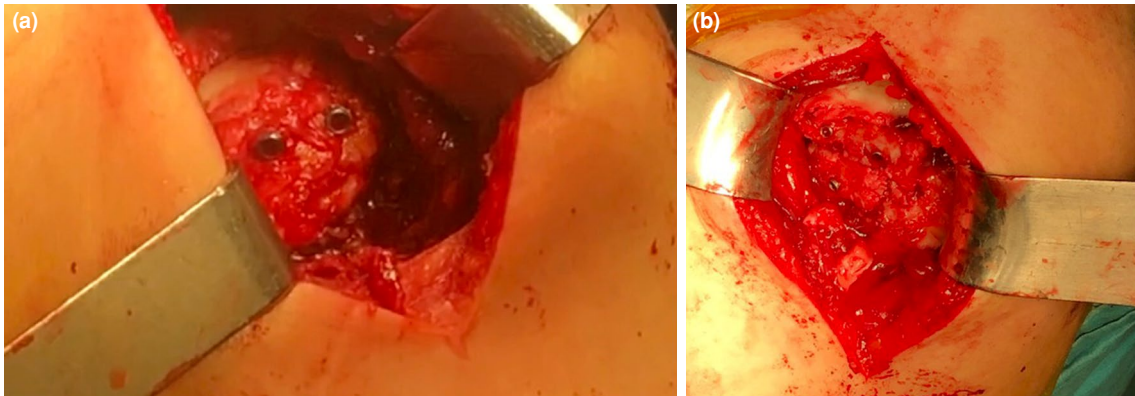


FIGURE 3. The intraoperative photograph was obtained with the patient in a beach chair position to show the anterior side of the humeral head. Take note of the headless screws that run from the anterior to the posterior of the humeral head to fix the transferred lesser tubercle to the remainder of the head, (a) two for the right and (b) three for the left.

The patient was mishandled with medical treatments and physical therapy, as the diagnosis was incorrect at other facilities. According to the CT, the patient was diagnosed with a neglected posterior shoulder dislocation, and our institution recommended surgery. However, when we evaluated the available CT axial sections, we diagnosed bilateral LPSD with a reverse Hill-Sachs lesion in 32% of the left shoulder and 36% of the right shoulder (Figure 1).

In this case, the modified McLaughlin procedure was performed two months apart, first on the dominant right and then on the left shoulder. The patient was seated in a beach chair position, and a preoperative C-arm image was obtained before starting the incision. Under cefazoline prophylaxis, the extended deltopectoral approach was used, referring to the paper by Gokkus et al.^[41] The subscapularis tendon was visualized by applying two deep retractors medially and laterally to the surgical field.

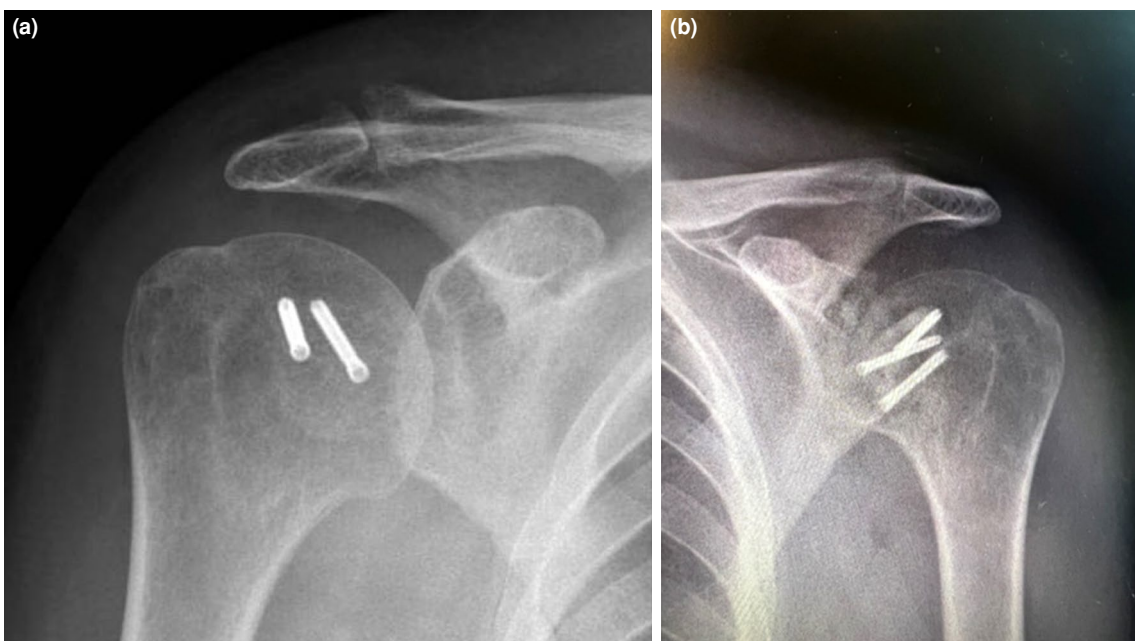


FIGURE 4. Postoperative anteroposterior radiograph of the shoulder showing that the shoulder is reduced and the head has the expected hemispheric appearance. (a) Right, (b) Left.

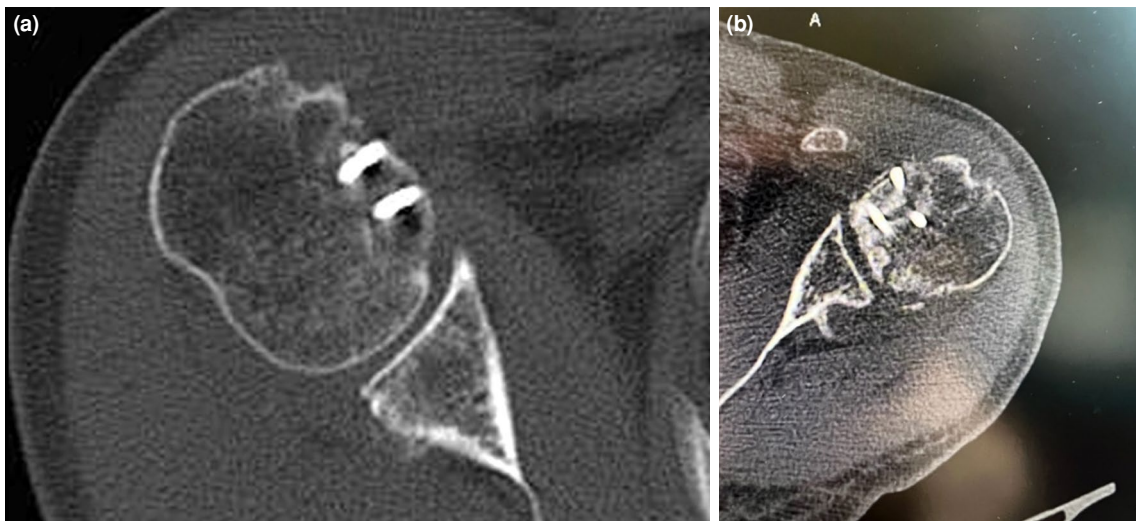


FIGURE 5. Postoperative computed tomography scan (axial views) showing that the reverse Hill-Sachs lesion has completely filled and disappeared. (a) Right, (b) Left.

The osteotomized lesser tuberosity, subscapularis tendon, and confluent capsule were detached medially. This approach provided a complete view of the head and the entire joint. Posterior subluxation of the head with impression fractures (32%) was noted. The long head of the biceps tendon was released from the glenoid attachment site. The subluxated portion of the head, which was posterior to the posterior glenoid rim, was removed by maneuvering it in an anterior direction with a Hoffman retractor, and reduction was achieved.

After the glenohumeral joint was reduced, the arm was rotated outward to visualize the wedge-shaped Hill-Sachs lesion at the humeral head (Figure 2). The bed of the reverse Hill-Sachs lesion was curved and drilled with a Kirschner wire (K-wire) to improve blood flow to the area. As the lesion was deep on the right shoulder, the bed of the lesion was filled with an autograft taken from the iliac wing. Later, the osteotomized lesser tuberosity with the subscapularis tendon was transferred to the Hill-Sachs lesion. Under fluoroscopy, fixation was performed with headless screws (two for the right shoulder and three for the left shoulder; Figure 3a, b). Postoperative radiographs revealed a reduced shoulder and the expected hemispheric appearance of the head (Figure 4a, b).

Postoperatively, the axial CT view indicated that the reverse Hill-Sachs lesion was entirely filled and disappeared (Figure 5a, b). In the postoperative rehabilitation, the shoulder was immobilized for four weeks with a simple shoulder-arm sling at 30° of

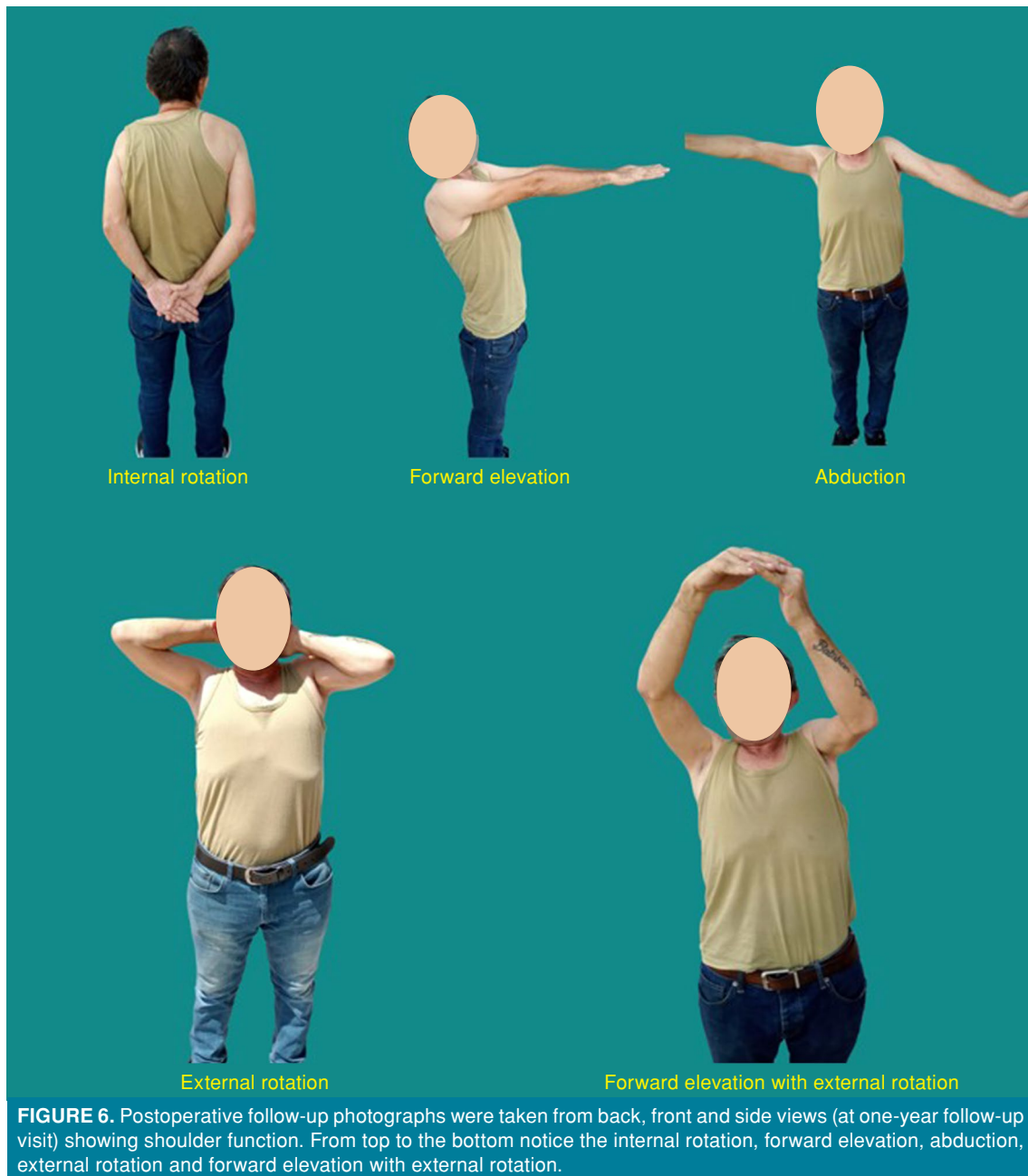
abduction and a neutral position. Immediately after surgery, pendulum exercises and passive abduction were started under the supervision of a physical therapist. Internal rotation was not allowed. At four weeks, active exercises and active-resistive exercises in all directions were started. At one-year follow-up, both shoulders were moderately functional: forward elevation left 70° and right 50°, abduction left 40° and right 60°, and internal rotation: the back of the hand could touch the fifth lumbar vertebra. Meanwhile, the patient did not suffer from recurrent dislocation. The pre- and postoperative Constant-Murley Scores (CMS) for the right and left shoulder were 30/52 and 11/48, respectively (Figure 6).

DISCUSSION

In this case report, bilateral shoulder surgery was performed to treat bilateral locked shoulders. This case report is striking, as it describes the treatment of the longest-overlooked posterior shoulder dislocation ever published.^[42]

The occurrence of an accompanying fracture, and the size of the reverse Hill-Sachs lesion determine the recommended treatment method.^[39] Several treatment options for the management of LPSDs have been published in the medical literature.

Closed reduction and immobilization in external rotation may be used to treat up to 25% of defects; for defects between 25 and 40%, transfer of the subscapularis tendon with (modified McLaughlin) or without lesser tuberosity (McLaughlin) or allograft/



autograft reconstruction may be used; and for defects greater than 50%, shoulder arthroplasty may be used.^[39]

The most common indications in the arthroplasty/reversed total arthroplasty group were comminuted fractures (four-part fracture-dislocations), impression fractures greater than 45%, advanced patient age, concomitant osteoarthritis, presence of an irreparable rotator cuff tear, and

presence of conditions, such as osteogenesis imperfecta.^[8,15,16,19-27]

Trauma is the most common cause of bilateral locked shoulder dislocation (n=52). Still, considering that, in one article, 26 of 35 patients were traumatic, disregarding this article, the most common cause is epileptic seizure (n=41). In five cases, the precipitating factor was an electric shock.^[1,8,12,14,17,35] The largest case series was reported by Schliemann et al.^[1]

Schliemann et al.^[1] studied 35 patients who presented with a blocked posterior shoulder dislocation during a 10-year study period. They concluded that patients who underwent surgical intervention to elevate and support the defect achieved significantly higher CMS than patients treated only with non-anatomic methods, such as the McLaughlin procedure, rotational osteotomy, or arthroplasty.^[1] In addition, Konda et al.^[37] published a video article demonstrating the successful use of the modified McLaughlin procedure to treat an acute posterior fracture-dislocation of the shoulder.

Cohen et al.^[32] conducted a single-center, retrospective study including 10 patients who had the modified McLaughlin procedure to treat persistent LPDS. In their series, their two cases were diagnosed approximately 56 to 52 weeks after from initial trauma, and those had 28 to 22 postoperative CMS, respectively. Compared to our report, the functional results in this study are poorer than our study. In addition, they suggested that the modified-McLaughlin approach had poor results, when used to treat cases with a delay of over six months between injury and surgery. In the literature, the diagnostic delay is usually no more than six months, but it is particularly striking that the delay in clinical diagnosis and good functional outcomes are disproportionate.^[1,32] This literature finding supports the clinical results of our current study.

According to the literature review, fresh injuries and intraoperatively reducible fractures (three-part and some simple four-part fractures), particularly those with less than 20% reverse Hill-Sachs lesions, were treated with the method of closed or open reduction and K-wire or internal fixation.^[11-16] In addition, the literature review revealed that a significant number of neglected (late presenting or overlooked) patients, particularly those with reverse Hill-Sachs lesions between 20 and 45%, were treated with the modified McLaughlin procedure.^[1,6,28-34,37]

Khira and Salama^[28] reported the results (n=12) of an open reduction and reconstruction of the humeral head defect using the McLaughlin technique modified by Hawkins et al.,^[10] in which the insertion of the subscapularis muscle was displaced with lesser tuberosity and augmented with a bone graft from the iliac crest fixed with screws. In their study, the time between dislocation and diagnosis ranged from four weeks to three months, with a mean of eight weeks.^[28] Compared to the literature, our case had the longest time interval between dislocation and surgery.

Kokkalis et al.^[29] presented a successful treatment of a patient with a bilateral neglected posterior

shoulder dislocation with a one-stage modified McLaughlin technique using absorbable suture anchors. Moreover, Elmali et al.^[30] treated a patient with a bilateral LPDS that was ignored for three months. In a single-stage operation, a humeral head defect on the right side covering more than 40% of the articular surface was treated using an osteochondral allograft femoral head. In contrast, a minor articular defect on the left side was treated with the modified McLaughlin technique using absorbable suture anchors. After 14 months, they reported satisfactory functional results and a stabilized shoulder.

Demirel et al.^[31] retrospectively reviewed the medical records of 23 patients diagnosed and treated for posterior shoulder dislocation. The authors applied the modified McLaughlin procedure to 13 patients with a reverse Hill-Sachs lesion ranging in size from 25 to 50%. They recommended using the modified McLaughlin procedure, involving transferring the lesser tuberosity with the subscapularis tendon attached to it into the defect.

In addition, Shams et al.^[6] studied 11 patients with a locked chronic posterior shoulder dislocation and reverse Hill-Sachs defects within the target range of 25 to 50% of the head size. They performed a modified McLaughlin procedure, using size five Ethibond® sutures to fix the lesser tuberosity and reported better functional results than we did, but these good results can be attributed to their earlier diagnosis of less than nine weeks.

Further, Guehring et al.^[16] described several surgical techniques for treating reverse Hill-Sachs lesions after posterior shoulder dislocation. The authors described long-term results that were followed for at least five years. Four patients with defects in less than 25% of the joint area were treated conservatively. One patient with a defect size greater than 40% had a glenohumeral arthroplasty implanted. Depending on the bone quality and lesion size, all remaining patients were treated using various surgical procedures.^[14] Twelve of 17 patients had a defect size of the humeral joint surface between 25 and 40%. Depending on the lesion size, these patients were treated with retrograde chondral elevation, an antegrade cylindrical graft, or an open iliac crest graft. Compared to our study, almost all cases in this study were diagnosed early. Therefore, their functional results can be expected to be better than those of our study.

In cases neglected for a long time or that cannot be diagnosed, the patient does not expect a complete recovery of shoulder motion, but avoiding shoulder

dislocation usually satisfies the patient. However, in severely delayed cases, due to the shortening and contracture of the surrounding soft tissues caused by the locked shoulder, prevention of recurrence of dislocation beyond complete recovery of years of restricted motion should be a priority. In this case report, the patient was satisfied with the clinical outcome, although ideal shoulder function had not yet been restored.

Although reverse/total arthroplasty is a popular treatment option as the last chance for comminuted fractures (particularly four-part fractures), it should be considered in cases with cuff tear arthropathy. Modified McLaughlin surgery with or without open reduction and internal fixation (ORIF) and allograft/autograft reconstruction produce favorable results in young patients and patients with adequate bone supply.^[1,6,28-37,39]

Recently, arthroscopic reverse-remplissage techniques have been published in orthopedic journals, reporting successful results (with good follow-up).^[17,18] However, despite these two successful reports, the author reports that the arthroscopic reverse-remplissage procedure requires a high degree of surgical skill and is associated with a long learning curve.

In conclusion, although the outcome of the surgery performed with the modified McLaughlin technique was not ideal, the patient appeared to be satisfied with the result, as no recurrence occurred. The modified McLaughlin technique is a method to address the pathophysiology of neglected posterior locked shoulder fracture dislocations by eliminating the reverse Hill-Sachs lesion, the major anatomic cause of locking and dislocation.

Patient Consent for Publication: A written informed consent was obtained from the patient.

Data Sharing Statement: The data that support the findings of this study are available from the corresponding author upon reasonable request.

Author Contributions: Idea/concept, design, critical review, control/supervision: M.S, K.G.; Data collection and processing, literature review, writing the article: K.G.

Conflict of Interest: The authors declared no conflicts of interest with respect to the authorship and/or publication of this article.

Funding: The authors received no financial support for the research and/or authorship of this article.

REFERENCES

- Schliemann B, Muder D, Gessmann J, Schildhauer TA, Seybold D. Locked posterior shoulder dislocation: Treatment options and clinical outcomes. *Arch Orthop Trauma Surg* 2011;131:1127-34. doi: 10.1007/s00402-011-1310-9.
- Price DD, Wilson SR (2006) Dislocations, shoulder. Available at: <http://www.emedicine.com/emerg/topic148.htm>. Accessed 14 April 2006
- Robinson CM, Akhtar A, Mitchell M, Beavis C. Complex posterior fracture-dislocation of the shoulder. Epidemiology, injury patterns, and results of operative treatment. *J Bone Joint Surg Am* 2007;89:1454-66. doi: 10.2106/JBJS.F.01214.
- Rouleau DM, Hebert-Davies J. Incidence of associated injury in posterior shoulder dislocation: Systematic review of the literature. *J Orthop Trauma* 2012;26:246-51. doi: 10.1097/BOT.0b013e3182243909.
- Saupe N, White LM, Bleakney R, Schweitzer ME, Recht MP, Jost B, et al. Acute traumatic posterior shoulder dislocation: MR findings. *Radiology* 2008;248:185-93. doi: 10.1148/radiol.2481071003.
- Shams A, El-Sayed M, Gamal O, ElSawy M, Azzam W. Modified technique for reconstructing reverse Hill-Sachs lesion in locked chronic posterior shoulder dislocation. *Eur J Orthop Surg Traumatol* 2016;26:843-9. doi: 10.1007/s00590-016-1825-4.
- Khayal T, Wild M, Windolf J. Reconstruction of the articular surface of the humeral head after locked posterior shoulder dislocation: A case report. *Arch Orthop Trauma Surg* 2009;129:515-9. doi: 10.1007/s00402-008-0762-z.
- Gavriilidis I, Magosch P, Lichtenberg S, Habermeyer P, Kircher J. Chronic locked posterior shoulder dislocation with severe head involvement. *Int Orthop* 2010;34:79-84. doi: 10.1007/s00264-009-0762-9.
- McLaughlin HL. Posterior dislocation of the shoulder. *J Bone Joint Surg [Am]* 1952;24 A:584-90.
- Hawkins RJ, Neer CS 2nd, Pianta RM, Mendoza FX. Locked posterior dislocation of the shoulder. *J Bone Joint Surg [Am]* 1987;69:9-18.
- Sharma A, Jindal S, Narula MS, Garg S, Sethi A. Bilateral asymmetrical fracture dislocation of shoulder with rare combination of injuries after epileptic seizure: A case report. *Malays Orthop J* 2017;11:74-6. doi: 10.5704/MOJ.1703.011.
- Wu J, Li L, Wang F, Lu S, Liu F, Jia H, et al. Bilateral posterior fracture-dislocation of the shoulders: Two rare case reports and literature review. *Medicine (Baltimore)* 2020;99:e22088. doi: 10.1097/MD.00000000000022088.
- Kasha S, Bandari G. Bilateral posterior fracture-dislocation of shoulder following seizures secondary to cavernous sinus venous thrombosis - A rare association. *J Orthop Case Rep* 2018;8:49-52. doi: 10.13107/jocr.2250-0685.1156.
- Claro R, Sousa R, Massada M, Ramos J, M Lourenço J. Bilateral posterior fracture-dislocation of the shoulder: Report of two cases. *Int J Shoulder Surg* 2009;3:41-5. doi: 10.4103/0973-6042.57935.
- Gurzì MD, De Meo D, Pugliese M, Di Giorgio L, Persiani P, Villani C. Bilateral posterior fracture-dislocation of the shoulder after epileptic seizure. *Trauma Case Rep* 2017;13:35-41. doi: 10.1016/j.tcr.2017.11.006.
- Guehring M, Lambert S, Stoeckle U, Ziegler P. Posterior shoulder dislocation with associated reverse Hill-Sachs lesion: Treatment options and functional outcome after a 5-year follow up. *BMC Musculoskelet Disord* 2017;18:442. doi: 10.1186/s12891-017-1808-6.

- Schliemann B, Muder D, Gessmann J, Schildhauer TA, Seybold D. Locked posterior shoulder dislocation:

17. Zwiebel X, Pelet S, Leclerc A. A modified reverse remplissage procedure for management of a locked posterior shoulder dislocation. *Case Rep Orthop* 2020;2020:8625368. doi: 10.1155/2020/8625368.
18. Bitar AC, Medina G, Ribas L, Smid J, Adoni T. Arthroscopic reverse remplissage in a bilateral seizure-related posterior shoulder dislocation: Technique description and 3-year follow-up case report. *Arch Bone Jt Surg* 2021;9:350-4. doi: 10.22038/abjs.2020.49649.2467.
19. Schmal H, Klemm C, Südkamp NP. Treatment and follow-up of a locked posterior shoulder dislocation. *Eur J Trauma* 2004;30:47-50. doi: 10.1007/s00068-004-1326-8.
20. Uppal HS, Robinson PW, Packham I, Crowther M. The management of bilateral posterior fracture dislocations of the shoulder: A case series illustrating management options. *Shoulder Elbow* 2016;8:111-7. doi: 10.1177/1758573215626105.
21. Popelka V. Chronic locked posterior shoulder dislocation treated by anatomical total shoulder arthroplasty. *Acta Chir Orthop Traumatol Cech* 2016;83:55-61. Czech.
22. Ivkovic A, Boric I, Cicak N. One-stage operation for locked bilateral posterior dislocation of the shoulder. *J Bone Joint Surg [Br]* 2007;89:825-8. doi: 10.1302/0301-620X.89B6.18842.
23. Kilicoglu O, Demirhan M, Yavuzer Y, Alturfan A. Bilateral posterior fracture-dislocation of the shoulder revealing unsuspected brain tumor: Case presentation. *J Shoulder Elbow Surg* 2001;10:95-6. doi: 10.1067/mse.2001.110568.
24. Cautero E, Gervasi E. Locked bilateral posterior fracture-dislocation of the shoulder in an epileptic patient: Case report. *Joints* 2014;2:146-8. doi: 10.11138/jts/2014.2.3.146.
25. Mnif H, Koubaa M, Zrig M, Zrour S, Amara K, Bergaoui N, et al. Bilateral posterior fracture dislocation of the shoulder. *Chir Main* 2010;29:132-4. doi: 10.1016/j.main.2009.11.001.
26. Murphy JD, Braunlich PR, Bansal M, Edge L, Harker JN. Bilateral posterior four-part fracture-dislocation of the proximal humerus after first-time seizure. *Cureus* 2021;13:e17688. doi: 10.7759/cureus.17688.
27. El Rassi G, Dib N, Maalouly J, Moukarzel R, Aouad D. Bilateral reverse total shoulder arthroplasty with soft tissue release for bilateral posterior fracture dislocation after status epilepticus. *Case Rep Orthop* 2021;2021:5525316. doi: 10.1155/2021/5525316.
28. Khira YM, Salama AM. Treatment of locked posterior shoulder dislocation with bone defect. *Orthopedics* 2017;40:e501-5. doi: 10.3928/01477447-20170308-07.
29. Kokkalis ZT, Mavrogenis AF, Ballas EG, Papagelopoulos PJ, Zoubos AB. Bilateral neglected posterior fracture-dislocation of the shoulders. *Orthopedics* 2012;35:e1537-41. doi: 10.3928/01477447-20120919-26.
30. Elmalı N, Taşdemir Z, Sağlam F, Gülabi D, Baysal Ö. One-stage surgical treatment of neglected simultaneous bilateral locked posterior dislocation of shoulder: A case report and literature review. *Eklemler Hastalıkları Cerrahisi* 2015;26:175-80. doi: 10.5606/ehc.2015.36.
31. Demirel M, Erşen A, Karademir G, Atalar AC, Demirhan M. Transfer of the lesser tuberosity for reverse Hill-Sachs lesions after neglected posterior dislocations of the shoulder: A retrospective clinical study of 13 cases. *Acta Orthop Traumatol Turc* 2017;51:362-6. doi: 10.1016/j.aott.2017.07.004.
32. Cohen M, Fonseca R, Galvão Amaral MV, Monteiro MT, Motta Filho GR. Treatment of chronic locked posterior dislocation of the shoulder with the modified McLaughlin procedure. *J Shoulder Elbow Surg* 2022;31:100-6. doi: 10.1016/j.jse.2021.05.026.
33. Chalidis BE, Papadopoulos PP, Dimitriou CG. Reconstruction of a missed posterior locked shoulder fracture-dislocation with bone graft and lesser tuberosity transfer: A case report. *J Med Case Rep* 2008;2:260. doi: 10.1186/1752-1947-2-260.
34. Kazamias K, Bisbinas V, Markopoulos G, Pellios S, Bisbinas I. Posterior shoulder dislocation with reverse Hill-Sachs lesion. A technical note and report of two cases. *SICOT J* 2021;7:24. doi: 10.1051/sicotj/2021022.
35. Ozer H, Baltacı G, Selek H, Turanlı S. Opposite-direction bilateral fracture dislocation of the shoulders after an electric shock. *Arch Orthop Trauma Surg* 2005;125:499-502. doi: 10.1007/s00402-005-0830-6.
36. Ryan J, Whitten M. Bilateral locked posterior shoulder dislocation in a footballer. *Br J Sports Med* 1997;31:74-5. doi: 10.1136/bjism.31.1.74.
37. Konda SR, Fisher N, Gage M, Egol KA. Posterior fracture dislocation of the shoulder: A modified McLaughlin procedure. *J Orthop Trauma* 2017;31 Suppl 3:S36-7. doi: 10.1097/BOT.0000000000000900.
38. Mi M, Zhang JM, Jiang XY, Huang Q. Management of locked posterior shoulder dislocation with reverse hill-sachs lesions via anatomical reconstructions. *Orthop Surg* 2021;13:2119-26. doi: 10.1111/os.13152.
39. Aydin N, Enes Kayaalp M, Asansu M, Karaismailoglu B. Treatment options for locked posterior shoulder dislocations and clinical outcomes. *EFORT Open Rev* 2019;4:194-200. doi: 10.1302/2058-5241.4.180043.
40. Riley DS, Barber MS, Kienle GS, Aronson JK, von Schoen-Angerer T, Tugwell P, et al. CARE guidelines for case reports: Explanation and elaboration document. *J Clin Epidemiol* 2017;89:218-35. doi: 10.1016/j.jclinepi.2017.04.026.
41. Gokkus K, Sığtas E, Kara H, Aydin AT. Posterior shoulder dislocation associated with the head (splitting) and humeral neck fracture: Impact of understanding radiologic signs and experience with an extended deltopectoral approach. *Tech Hand Up Extrem Surg* 2018;22:57-64. doi: 10.1097/BTH.0000000000000190.
42. Atik OŞ. Which articles do the editors prefer to publish? *Jt Dis Relat Surg* 2022;33:1-2. doi: 10.52312/jdrs.2022.57903.